

**EVALUATION OF RESULTS OF VOLAR  
PLATING IN DISTAL END RADIUS  
FRACTURES : A RETROSPECTIVE AND  
PROSPECTIVE STUDY**



**DISSERTATION SUBMITTED TO  
UNIVERSITY OF SEYCHELLES  
AMERICAN INSTITUTE OF MEDICINE**

**IN PARTIAL FULFILLMENT OF THE REQUIREMENTS  
FOR THE DEGREE**

**M.Ch (Orthopaedic Surgery)**

By

**DR. Gyneshwar Tank**  
M.S. (Orthopaedics)

**April 2011**

## **INTRODUCTION**

Fractures of lower end radius are most common fractures of the upper extremity, encountered in practice and constitute 17 % of all fractures and 75% of all forearm fractures<sup>[1]</sup>.

Close reduction and cast immobilization has been the mainstay of treatment of these fractures but malunion of fracture and subluxation /dislocation of distal radioulnar joint resulting in poor functional and cosmetic results is the usual outcome<sup>[2]</sup>. The residual deformity of wrist adversely affects wrist motion and hand function by interfering with the mechanical advantage of the extrinsic hand musculature<sup>[3]</sup>. It may cause pain, limitation of forearm motion, and decreased grip strength as a result of arthrosis of the radiocarpal and distal radioulnar joints<sup>[4]</sup>.

As open reduction and volar plating ensures more consistent correction of displacement and maintenance of reduction, this study evaluates the anatomical and functional outcome of open reduction and plate fixation in the management of fracture distal end radius in thirty patients.

## **AIMS AND OBJECTIVES**

1. To assess the role of open reduction and plate fixation followed by early mobilization of wrist joint in the management of fracture distal end radius.
2. To assess the functional results and complications of this technique.

## **REVIEW OF LITERATURE**

Fractures of the distal radius have been discussed in Orthopaedic literature for over 200 years<sup>[5]</sup>. The fracture patterns were described even before the advent of radiography. Although Pouteau, a french surgeon may have described this fracture pattern earlier, Abraham Colles is generally credited with description of the most common fracture pattern affecting the distal end radius. Colles' fracture refers only to extra-articular fractures with dorsal displacement of the distal fragment. The other fracture patterns of the distal radius were described by Smith (a pattern of volar displacement of the distal fracture occurring 0.5 to 1 inch proximal to the articular surface).

Distal radial fractures have a bimodal age distribution, consisting of a younger group who sustains relatively high-energy trauma to the upper extremity and an elderly group who sustains both high-energy injuries and insufficiency fractures.<sup>[6]</sup>

**Bartosh and Saldana (1990)**<sup>[7]</sup> believe that when close reduction is performed, the thicker palmar ligaments are brought out to length and pull on the distal fragment before the thinner dorsal ligaments exert any traction. The dorsal ligaments are oriented in a relative “Z” orientation, which allows them to lengthen with less force than the more vertically oriented palmar ligaments. This limits the ability of any technique of closed traction reduction to accurately restore palmar tilt.

**Rikkli et al (1996)**<sup>[8]</sup> interpreted the wrist as consisting of three distinct columns, each of which is subjected to different forces. This theory emphasizes that, (1) the lateral, or radial, column is an osseous buttress for the carpus and is an attachment point for the intracapsular ligaments; (2) the intermediate column functions in primary load transmission and may be considered the cornerstone of the radius because it is critical for both articular congruity and distal radioulnar function; and (3) the medial, or ulnar, column serves as an axis for forearm and wrist rotation as well as a post for secondary load transmission.

**Szabo (2006)**<sup>[9]</sup> documented that, although the distal radio-ulnar joint is primarily stabilized by the triangular fibrocartilage complex (TFCC), additional stability is imparted by the joint capsule, interosseous membrane, pronator quadratus, and extensor carpi ulnaris.

### **MECHANISM OF INJURY**

Distal radius fractures usually occur after a fall on the wrist. The type of fracture that occurs depends on the rate of loading and the magnitude and direction of the load. The point of application of force will determine whether there is a radius fracture, or a carpal fracture or a dislocation. Ninety percent of the radius fractures are caused by stress loading with the wrist in dorsiflexion.

**Smith (1854)**<sup>[10]</sup> claimed that fractures of the distal radius with palmar displacement results from a fall on the back of the flexed hand.

**Frykman (1967)**<sup>[11]</sup> stated that, a fall on the outstretched hand with the wrist in 40° to 90° of dorsiflexion produces a distal radius fracture with dorsal displacement.

**Weber (1987)**<sup>[12]</sup> reported that, as the fracture line propagates dorsal to the midaxial plane, the dorsal bone develops multiple fracture lines commonly recognized as comminution and that, the angle and the force of impact determine the fracture pattern. Distal radius fractures occurring from high loading angles (70° to 90°) will typically comminute highly, while those fractures occurring from low loading angles (20° to 40°) are typically low energy and minimally comminuted. Greater than 90° of wrist dorsiflexion usually results in carpal injuries.

## **CLASSIFICATIONS**

Traditionally, classification systems are used to categorize injuries and direct treatment based on expected outcome.

**Frykman (1967)**<sup>[13]</sup> introduced the involvement of the ulna in distal radius fractures. He established the homonymous classification system, which specifies the intra-articular or extra-articular nature of the fracture, the individual participation of radiocarpal and distal radioulnar joints, in combination with the existence or not of ulna's styloid process fracture. The system, as mentioned above, is unable to provide quantitative determination about the extension, the direction or the initial fracture dislocation, the degree of comminution and the shortening. Hence, it has limited prognostic capacity about the suggested treatment.

**Melone (1984)**<sup>(14)</sup> heralded the contemporary classifications by observing that there were four components of the radiocarpal joint and that intra-articular fractures appeared to fall into five basic patterns.

**The Swiss Association for the Study of Internal Fixation (AO/ASIF) group** developed the “Comprehensive Classification of Fractures of Long Bones” to serve as a basis for treatment and evaluating results. The distal radius and ulna are designated as ‘23’ and is further classified into three types. Each type is classified into three groups and each group into three subgroups.

23A – Extra-articular Fracture

A1 – Extra-articular fracture of the ulna, radius intact

A2 – Extra-articular fracture of the radius, simple and impacted

A3 - Extra-articular fracture of the radius, multifragmentary

23B – Partial articular fracture wherein the fractures involve only part of the articular surface, while rest of that surface remains attached to the diaphysis.

B1 – Partial articular fractures of the radius, saggital

B2 – Partial articular fracture of the radius, dorsal rim (Barton)

B3 – Partial articular fracture of the radius, volar rim (reverse Barton)

23C – Complete articular fracture, wherein, the articular surface is disrupted and completely separated from the diaphysis.

C1 – Complete articular fracture of the radius, articular simple, metaphyseal simple

C2 – Complete articular fracture of the radius, articular simple, metaphyseal multifragmentary

C3 – Complete articular fracture of the radius, multifragmentary

***Modified AO Classification***

It is simplified to 5 Intra-articular fractures

A – Extra-articular, B – Partial articular, B1 : Radial Styloid

B2 : Dorsal rim fractures, B3 : Volar rim fractures, B4 : Die Punch fractures, C – Complete articular

The only modification to the AO system was the addition of the "die-punch" fracture to the partial articular fractures group.

### **RADIOGRAPHIC ASSESSMENT**

Radiographic imaging is important in diagnosis, classification, treatment and follows up assessment of these fractures.

The parameters assessed in the posteroanterior view include

1. **Radial angulation or inclination** – is the relative angle of the distal radial articular surface to a line perpendicular to the long axis of the radial shaft. This averages 23 degrees (range, 13 to 30 degrees).
2. **Radial length** – relates the length of the radius to the ulna by distance between two perpendicular lines to the long axis of the radius, one joining the tip of the radial styloid process and the other, the surface of ulnar head. This averages 11 mm (range, 8 to 18 mm).
3. **Ulnar variance** – is the vertical distance between the distal ends of the medial corner of the radius and the ulnar head.
4. **Radial Shift (Width)** – is the displacement of the distal fragment in relation to the radial shaft and is measured as the distance between the longitudinal



axis through the centre of radius and the most lateral point of the radial styloid.

**Metz and Gilula (1993)**<sup>[15]</sup> stated that, the routine minimal evaluation for distal radius fractures must include the postero-anterior and the lateral views.

Guidelines for acceptable closed reduction as given by **Nana AD et al (2005)**<sup>[16]</sup> include

1. Radial inclination : greater than or equal to  $15^{\circ}$  on the postero-anterior view.
2. Radial length: less than or equal to 5 mm shortening on postero-anterior view.
3. Radial Tilt : less than  $15^{\circ}$  dorsal or  $20^{\circ}$  volar tilt on lateral view.
4. Articular incongruity : less than 2 mm of step off.

Radiographic signs that alert the surgeon, that the fracture is probably unstable and closed reduction alone will be insufficient include the following<sup>[17]</sup>:

- a) Dorsal comminution greater than 50% of the width laterally
- b) Palmar metaphyseal comminution
- c) Initial dorsal tilt greater than 20 degrees
- d) Initial displacement (fragment translation) greater than 1 cm
- e) Initial radial shortening more than 5 mm
- f) Intra-articular disruption

- g) Associated ulna fracture
- h) Severe osteoporosis

## **TREATMENT MODALITIES**

### **Closed reduction**

It relies on the principle of ligamentotaxis to reduce fracture fragments. No control can be expected for depressed articular fragments that lack ligament attachment.

**Jones (1915)**<sup>[18]</sup> suggested a manipulative method of reduction, involving increasing the deformity, applying traction and placing the hand and wrist in reduced position.

**Bohler (1929)**<sup>[19]</sup> described passive assisted gravity method of reduction.

**Connolly (1995)**<sup>[20]</sup> reduced the fractures by reversing the original mechanism of injury.

Several factors have been associated with re-displacement following closed manipulation of a distal radius fracture:

1. The initial displacement of the fracture.
2. The age of the patient.
3. The extent of metaphyseal comminution (the metaphyseal defect).
4. Displacement following closed treatment is a predictor of instability.

### **Cast Immobilization**

**Charnley et al (1950)**<sup>[21]</sup> gave the traditional cast technique, that uses three pressure areas, giving three point moulding by placing a mould (pressure) dorsally over the dorsal fragment, volarly and dorsally over the mid forearm and palmarly over the distal aspect of proximal fragment.

**Sarmiento and associates (1975)**<sup>[22]</sup> recommended immobilization of forearm in supination, when there is associated involvement of the distal radioulnar joint, so as to hold the joint in the reduced position.

The ideal forearm position, duration of immobilization, and need for a long or a short arm cast remains controversial; no prospective study has demonstrated the superiority of one method over another. The final results are primarily determined by the original displacement and final reduction.

**Weber ER (1987)**<sup>[23]</sup> documented that collapse of the fracture is unavoidable because the compressive forces generated by the tendons of flexor and the extensor muscles crossing the wrist cannot be counteracted by the supporting plaster.

### **Percutaneous Pin Fixation**

Percutaneous pinning techniques are an attempt to bridge the therapeutic gap between external fixators.

**Lambotte in 1908**<sup>[24]</sup> suggested single pin placement through the radial styloid as a means of stabilizing the distal radius fracture.

**Kapandji in 1976**<sup>[25]</sup> first described two pin intrafocal pinning. Fractures with volar comminution, fractures with any articular displacement and fractures with more than “minimal articular involvement” are reported contraindications.

**John M. Rayhack in 1989** and again in **1991**<sup>[26]</sup> reported the technique of ulnar- radial pinning with fixation of the distal radio-ulnar joint following reduction by ligamentotaxis and manual manipulation of the distal fragment. This technique does not apply to Smith fracture with volar comminution.

### **External Fixation**

**Anderson and O’Niel (1944)**<sup>[27]</sup> described the use of external fixator for treating fractures of the distal radius using the principle of ligamentotaxis. The external fixator is applied to maintain the distraction afforded by traction and serves as a neutralization device.

**Agee (1993)**<sup>[28]</sup> found that palmar translation of the hand is necessary to restore palmar tilt. The external fixator designed by John Agee, MD (Hand Biomechanics Lab, Sacramento, CA) is one of the newer fixators available that allows plantar translation while achieving longitudinal traction for the reduction of the distal radius fractures.

External fixators could be combined with percutaneous pin manipulation of key fragments, percutaneous screw fixation of larger fragments, or open reduction and internal fixation .

### **Open Reduction and Internal Fixation By Plates**

Surgical treatment (plating in particular) ensures more consistent correction of displacement and maintenance of reduction. The choice of surgical technique for reduction and fixation depends on fracture displacement, joint surface involvement, patient age, bone quality, handedness, occupation, and avocation. Surgeon experience and preference also dictates the treatment method.

### **Volar plates versus dorsal plates**

**Campbell DA (2000)** and **Kamano M (2002)**<sup>[29]</sup> reported a high rate of complications with dorsal plate placement such as tendon adherence, joint stiffness, and risk of extensor tendon irritation or even rupture. With the advent of new fixed-angle screw-plate designs, volar fixation should be the standard approach for distal radius fractures with joint congruity. A volar plate placement through a flexor carpi radialis approach affords a soft tissue layer between the skin and the plate that may have greater depth than a dorsal approach.

The rationale for volar exposure and volar plate fixation is that in most high-energy distal end radius fractures there is substantial comminution of the dorsal

articular rim of the radius making it difficult to fully visualize the articular surface and reduce it anatomically and maintain it.

Volar plates fall into four functional categories: buttress plates (with or without distal screws), tine or blade plates, fixed-angled locking plates, and polyaxial locking plates.

**Rozental T (2006)**<sup>[30]</sup> reported that volar plating is not immune to the extensor tendon complications that affect dorsal plates. The complications of volar plates such as irritation of the flexor carpi radialis and flexor pollicis longus tendon by the plate itself as well as dorsal tendon irritation from screw prominence have been reported.

### **Distraction plating**

**Burke and Singer(1998)**<sup>[31]</sup> introduced the use of internal distraction plating or bridge plating for distal radius fractures with severe metaphyseal-diaphyseal comminution. The technique was further expanded by **Ruch and colleagues(2005)**, who described the use of a 3.5-mm plate (Synthes, Paoli, Pennsylvania) to span from the intact radial diaphysis to the third metacarpal.

### **Locking versus nonlocking plates**

**Paul A. Martineau et al in Orthop Clin N Am 38 (2007)** documented that, the locking nature of the screw-plate construct produces fixation even in bone defects and osteopenic bone and permits early range of motion exercises. In contrast to external fixation and percutaneous pinning, no tethering of muscle,

tendon, or capsule occurs with plate fixation and therefore motion of the wrist and fingers is uninhibited. These advantages would permit earlier and more aggressive rehabilitation and more rapid regain of function.

## **COMPLICATIONS**

The rate of complications of volar locking plates varies from 8% to 32%.<sup>[32]</sup>

### **Infection**

Compound fractures and fractures treated operatively are at risk for infection. The largest reported series of compound fractures by **Rozental TD, Beredjiklian PK, Steinberg DR, et al (2002)**<sup>[33]</sup> reported a 44% infection rate, with 62% of the infections involving the soft tissues and 38% as osteomyelitis.

### **Extensor Tendon Irritation or Rupture or Nerve Injury**

**Bonatz E, Kramer TD, Masear VR (1996)**<sup>[34]</sup> documented that, tendon ruptures can occur as an early or late complication and the extensor pollicis longus tendon is most commonly ruptured.

**Gelb RI (1995)**<sup>[35]</sup> reported that the ruptured tendon usually cannot be directly repaired and function can be well restored by performing an extensor indicis proprius tendon transfer.

**Rozental TD et al in 2006**<sup>[36]</sup> reported dorsal tendon irritation from screw prominence.

**Arora et al (2007)**<sup>[37]</sup> found that more than half of the complications were tendon ruptures or tenosynovitis with an incidence of 16%. Careful drilling and choice of screw length is important to avoid these complications.

### **Placement of the Distal Screws into the Radiocarpal Joint**

**McQueen (1988)**<sup>[38]</sup> originally pointed out that the distal screws should support the subchondral bone, requiring the placement of the plate as distally as possible, and yet not so far as to place the screws into the joint.

### **Irritation or Rupture of Flexor Tendons**

**Drobtz and Kutscha-Lissberg (2003)** reported rupture of flexor pollicis longus (FPL) is the most frequent complication of locking screw volar plate fixation, occurring in 12% of patients.

**Raymond K et al (2007)** noticed that the prominent radial end of the plate at the wrist causes skin irritation and rupture of flexor tendons.

Placement of the volar plate is important . If the plate is placed too distally, the flare of the volar rim of the joint will cause the plate to be prominent along its distal margin . This will be the part of the radius (or plate) that is closest to the flexor tendons and therefore at greatest risk of injuring them.

### **Prominent Hardware that is Clinically Palpable Volarly**

volar radial tuberosity is quite subcutaneous, with little overlying fat. Plates that are placed too radially can be easily palpated by the patient.



**Inability to Remove a Plate/Screws**

**Hertel R et al (1996)**<sup>[39]</sup> reported complications related with the plate removal from forearm bones. They reported the major complications such as refracture, wound sepsis, and nerve damage.

**Hamilton et al (2004)** suggested the stripping of the locking screw heads resulted from the cold welding or cross threading between the screw head and the plate rather than the purchasing between the screw threads and the bone.

**Nonunion/delayed union**

**Mckee MD, Waddell JP, Yoo D, et al (1997)** and **Prommersberger KJ, Fernandez DL (2004)**<sup>[40]</sup> reported open fractures, severe comminution, infection, tissue interposition, devascularization of the bone ends, and pathologic lesions as risk factors for nonunion. They also reported nonunion of the distal radius associated with nonunion of a distal ulna fracture.

**Fernandez DL, Ring D, Jupiter JB (2001)** categorized fractures that show no radiographic signs of bridging trabeculae across the fracture site at 4 months as delayed unions and as nonunions after 6 months. Nonunion of the distal radius is uncommon.

**Malunion**

Although malunion may not cause significant problems in low-demand elderly patients , a weak, deformed, and painful wrist may result in young, active patients (**McQueen M, Caspers J**).

**Fernandez DL (1993) and Park MJ, Cooney WP, Hahn ME, et al (2002)<sup>[41]</sup>** extensively evaluated malunited distal radius fractures.

## **MATERIALS AND METHODS**

This is a retrospective and prospective study carried out on the patients with fractures of the distal end radius, attending the outdoor and the emergency services of Sardar Vallabh Bhai Patel Hospital, Meerut, who gave their consent to undergo the procedure. Thirty patients with fractures of the distal radius were included in the study.

The exclusion criteria were -

1. Patients with comorbid conditions preventing surgical intervention
2. Patients with more than 3 weeks duration of injury
3. Patients with immature skeleton
4. Patients with local tissue condition making the surgery inadvisable

All the patients were subjected to clinical examination. Radiographic evaluation of the affected & the normal side was done at the time of injury with the antero-posterior and lateral views. The radiographs were assessed in terms of loss of palmar tilt or presence of dorsal tilt, radial shortening and loss of radial inclination. Fractures were classified as according to the AO Classification into type A (extra-articular), type B (partial articular) or type C (complete articular). After pre-anaesthetic evaluation patients were taken up for surgery.



### SURGICAL TECHNIQUE-

All procedures were performed under general or regional anaesthesia. Our standard practice was preoperative prophylactic intravenous ceftriaxone and usage of tourniquet and bipolar diathermy for homeostasis. The standard volar approach was undertaken to fix the fragments. In cases initially approaching the radial styloid fragment, dissection between the flexor carpi radialis tendon and radial artery were used. For the die-punch volar fragment, dissection between the median nerve and flexor carpi radialis tendon was used. The distal and radial borders of pronator quadratus were lifted and retracted ulnarly. Open reduction was performed with the aid of intrafocal leverage, traction by an assistant/distractor, and provisional fixation by temporary Kirschner wires followed by definitive volar buttress or locking plate and screws. Image intensifier was used in theatre to assist the evaluation of fracture reduction and fixation.

### POSTOPERATIVE PROTOCOL

Postoperatively radiographs were taken, the limb was kept elevated in above elbow plaster slab, active finger and shoulder exercises were started at the earliest possible. The plaster slab was removed after 10 days, crepe bandage applied and active exercises of wrist, elbow and shoulder were started.

### EVALUATION OF OUTCOME

The patients were followed up for minimum of 54 wks. Clinical, radiological and functional reviews were performed at periodic intervals.

RADIOLOGICAL

Radiological assessment was done in terms of residual dorsal angulation, radial shortening and loss of radial inclination and the results were graded according to the *Sarmiento's modification of Lind Strom Criteria*<sup>[42]</sup>. These parameters were assessed during the follow up of the patient to assess the quality of reduction and the ability of the technique to maintain the reduction.

ANATOMICAL EVALUATION –  
SARMIENTO'S MODIFICATION OF LIND STORM CRITERIA

	DEFORMITY	RESIDUAL DORSAL TILT	RADIAL SHORTENING	LOSS OF RADIAL INCLINATION
<b>EXCELLENT</b>	No or insignificant	0 <sup>0</sup>	< 3 mm	< 5 <sup>0</sup>
<b>GOOD</b>	Slight	1 <sup>0</sup> to 10 <sup>0</sup>	3 to 6 mm	5 <sup>0</sup> to 9 <sup>0</sup>
<b>FAIR</b>	Moderate	11 to 14	7 to 11 mm	10 <sup>0</sup> to 14 <sup>0</sup>
<b>POOR</b>	Severe	Atleast 15 <sup>0</sup>	Atleast 12 mm	>14 <sup>0</sup>

CLINICAL AND FUNCTIONAL

Functional evaluation of the patients was done at the last follow up according to the *demerit point system of Gartland and Werley*<sup>1</sup> with *Sarmiento et al's modification*.

**DEMERIT POINT SYSTEM USED TO EVALUATE END RESULTS OF HEALED COLLES' FRACTURES**

<b>RESULT</b>	<b>POINTS</b>
<b>RESIDUAL DEFORMITY</b>	
Prominent Ulnar Styloid	1
Residual Dorsal Tilt	2
Radial Deviation of Hand	2 to 3
Point Range	0 to 3
<b>SUBJECTIVE EVALUATION</b>	
Excellent: no pain, disability or limitation of motion	0
Good: Occasional pain, slight limitation of motion, no disability	2
Fair: Occasional pain, some limitation of motion, feeling of weakness in wrist, no particular disability if careful, activities slightly restricted	4
Poor : Pain, limitation of motion, disability, activities more or less markedly restricted	6
Point Range	0 to 6
<b>OBJECTIVE EVALUATION*</b>	
Loss of Dorsiflexion	5
Loss of Ulnar Deviation	3
Loss of Supination	2
Loss of Palmar Flexion	1
Loss of Radial Deviation	1
Loss of Circumduction	1
Loss of Pronation	2
Pain in Distal Radioulnar Joint	1
Grip Strength – 60% or less of opposite side	1
Point Range	0 to 5
<b>COMPLICATIONS</b>	
Arthritic Change	
Minimum	1
Minimum with Pain	3
Moderate	2
Moderate with pain	4
Severe	3
Severe with pain	5
Nerve Complications (Median)	1 to 3
Poor Finger Functions Due to Cast	1 to 2
Point Range	0 to 5
<b>END RESULT POINT RANGES</b>	
Excellent	0 to 2
Good	3 to 8
Fair	9 to 20
Poor	21 & Above

\*The objective evaluation is based on the following ranges of motion as being the minimum for normal function: dorsiflexion 45° ; palmar flexion 30°; radial deviation 15°; ulnar deviation 15° ; pronation 50° ; supination 50°

## **OBSERVATIONS AND RESULTS**

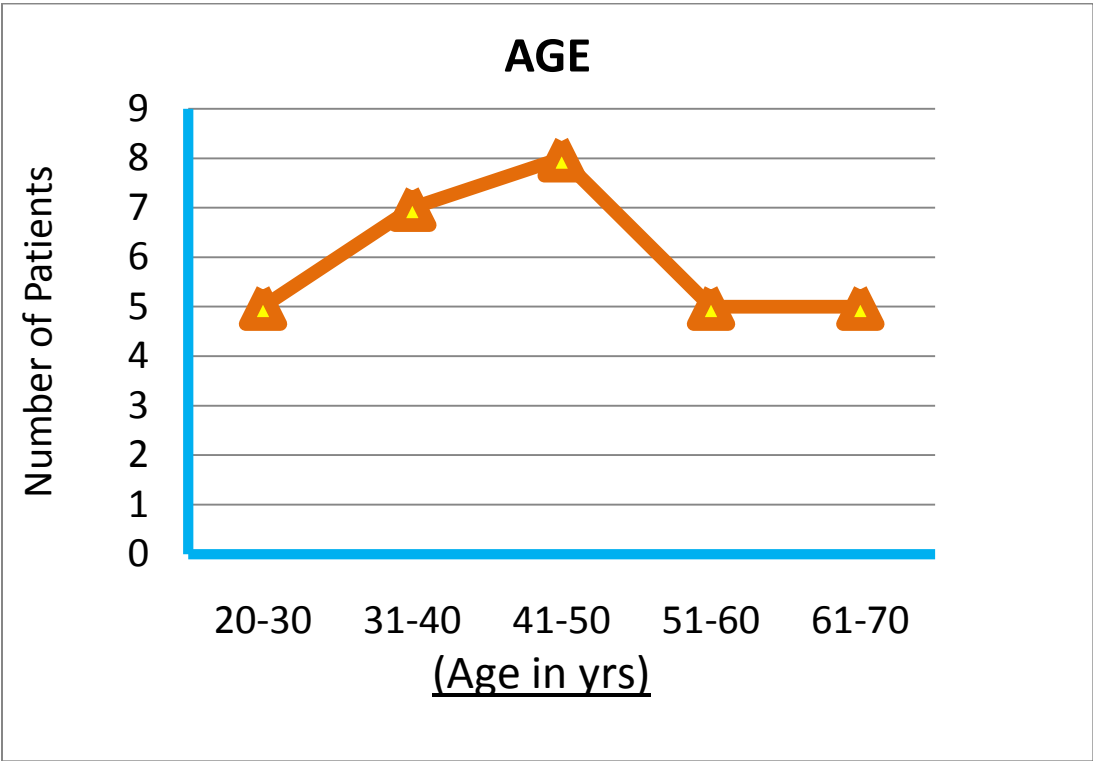
The study comprised a total of thirty patients of fractures of the distal radius presenting to S.V.B.P. Hospital, Meerut during February 2008 to February 2011

### **AGE & SEX DISTRIBUTION**

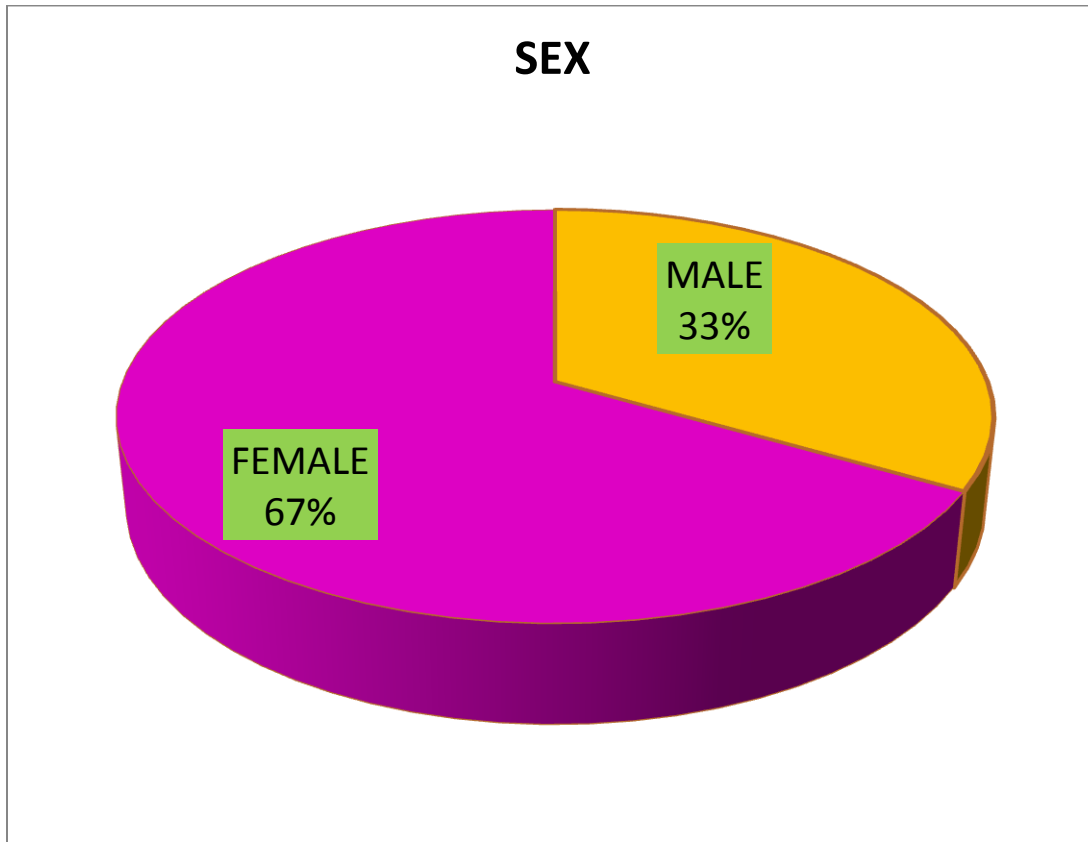
<b>AGE(yrs)</b>	<b>FEMALE</b>	<b>MALE</b>	<b>Total</b>
20-30	2	3	5
31-40	4	3	7
41-50	6	2	8
51-60	3	2	5
61-70	5	0	5
<b>Total</b>	<b>20</b>	<b>10</b>	

The mean age of the patients taken up for the study was 42.6 years with the youngest patient being 20 years and the oldest being 70 years.

There were 10 male patients (33%) and 20 female patients (67%).







MODE OF TRAUMA & TYPE OF FRACTURE (AO Classification)

	<b>TYPE A</b>	<b>TYPE B</b>	<b>TYPE C</b>	<b>Total</b>
<b>FALL</b>	6	0	12	18
<b>RTA</b>	2	4	6	12

<b>Total</b>	8	4	18	
--------------	---	---	----	--

The mode of injury was fall in 18 cases (60%), road traffic accident in 12 cases (40%).

8 fractures were classified as AO type A, 4 fractures as AO type B and 18 fractures as AO type C.

### ULNAR STYLOID FRACTURE

Ulnar Styloid was fractured in 9 cases (30%) and intact in 21 cases (70%). The fracture was managed expectantly.

### TIME LAPSE BETWEEN INJURY AND SURGERY

Most of the cases were operated on the same day or the next day of attending the OPD or the emergency.

Out of the 30 cases, 24 cases (80%) were operated within a week of injury and 6 cases (20%) between 8-14 days. The delay, if any was on the part of the patients presenting late.

### DURATION OF FOLLOW UP

The average duration of follow up was 39.6 weeks with minimum of 24 weeks and maximum of 58 weeks.

<b>DURATION OF FOLLOW UP</b>	<b>NUMBER OF PATIENTS</b>
------------------------------	---------------------------

24-35 wks	13
36-47 wks	10
48-59 wks	7
Total	30

### **ANATOMICAL EVALUATION**

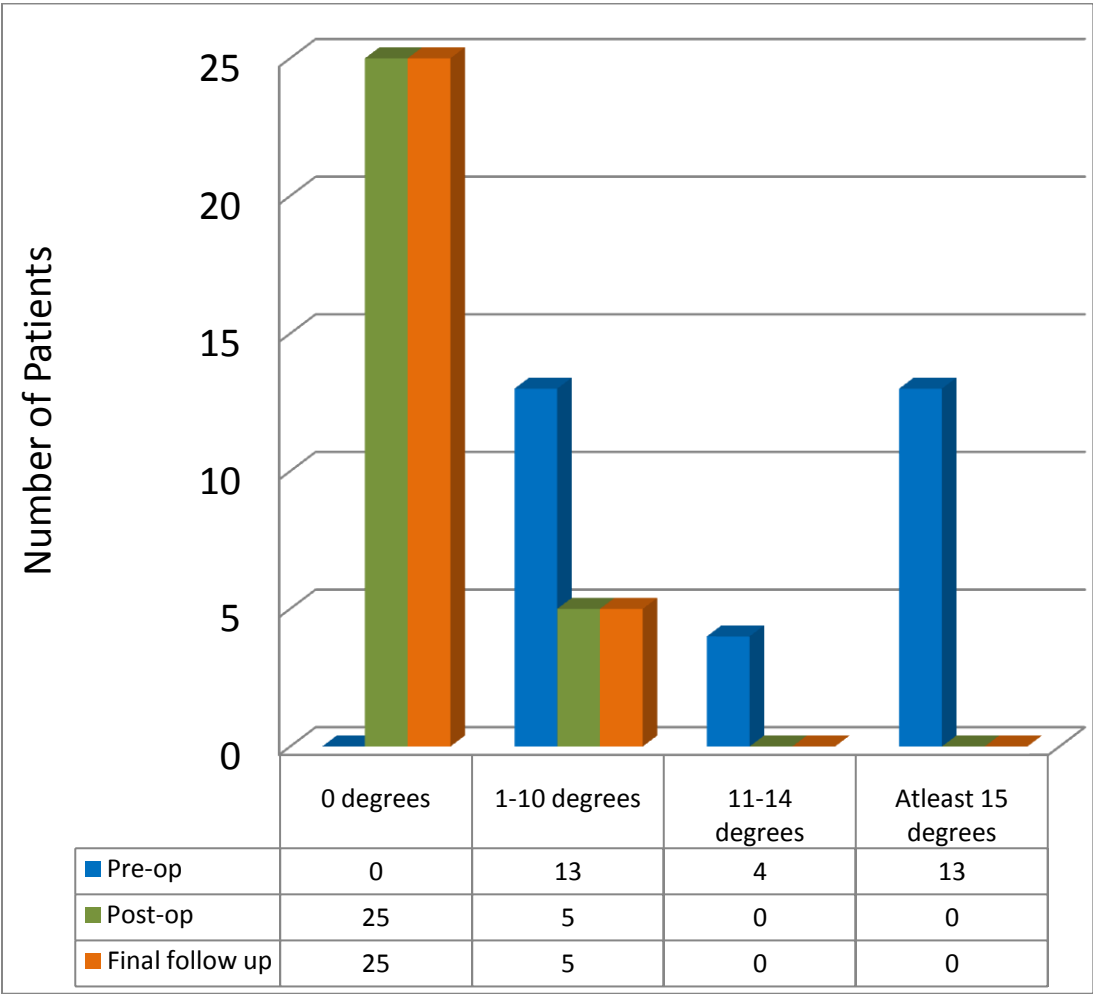
#### **RESIDUAL DORSAL TILT**

The dorsal tilt (from a neutral of 0 degrees) of the distal radial articular surface varied from 4 degrees to 26 degrees. The dorsal tilt decreased from an average of 13<sup>0</sup> before the reduction to an average of 0.6<sup>0</sup> at the most recent follow up evaluation.

Postoperatively the dorsal tilt could be corrected to the anatomical palmar tilt or atleast a neutral angle in 25 patients (83%) while in 5 patients (17%) the dorsal tilt could not be restored even to a neutral angle. Out of these 5 patients, 3 had an AO type C fracture while 2 had an AO type A fracture.

At the final follow up, one patients (3%) had some loss of correction of dorsal tilt. This patient had a comminuted intra-articular fracture (AO Type C). In 97% of the patients the correction of tilt achieved at surgery was maintained till healing.

<b>RESIDUAL DORSAL TILT</b>
-----------------------------



RADIAL LENGTH

The radial shortening varied from 4mm to 26 mm. It decreased from an average of 11 mm before the reduction to an average of 0.65 mm postoperatively and to 0.8 mm at the most recent follow up.

In 1 patient (3%) there was 4 mm of collapse of radial length from the immediate postoperative to the final follow up period. This patient had AO type C .

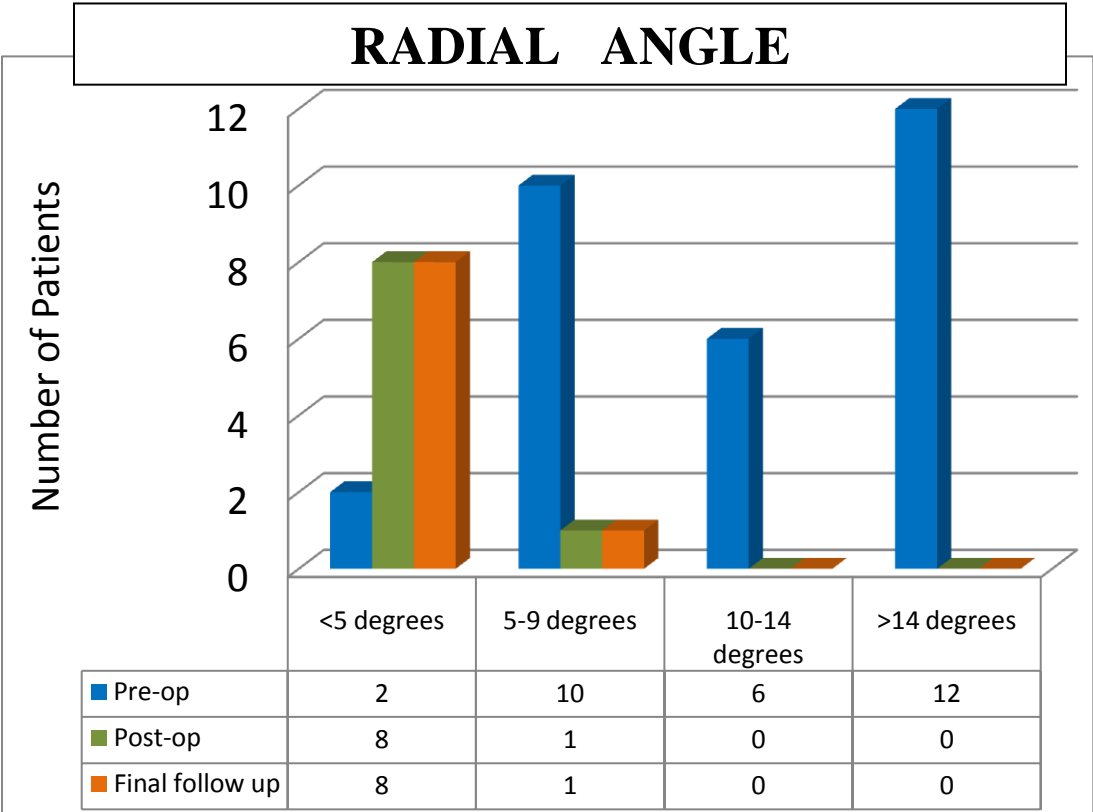
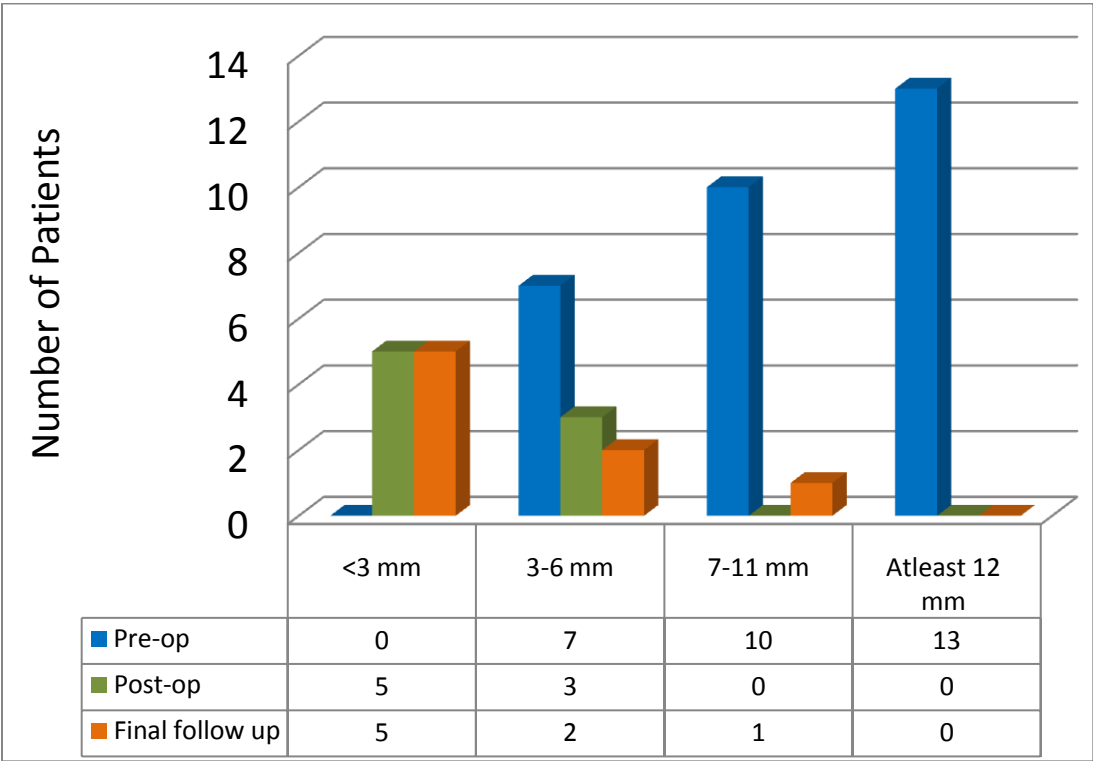
97% of the fractures maintained there postoperative radial length till union.

### RADIAL ANGLE

The loss of radial inclination varied from 0 degrees to 20 degrees. It from an average of 12.1 degrees before reduction to an average of 0.9 degree postoperatively to 1 degrees at the final follow up.

In 1 patient (3%) there was loss 3 degrees of correction of radial inclination. This patient had an AO Type C fracture.

<b>RADIAL LENGTH</b>
----------------------



**CLINICAL AND FUNCTIONAL EVALUATION**

**RESIDUAL DEFORMITY**

Prominent Ulnar Styloid – 3 patients (10%)

Residual Dorsal Tilt – 3 patients (10%)

Radial Deviation of hand – 0 patients (0%)

**SUBJECTIVE EVALUATION**

Subjectively ,out of 30 patients,21 patients (70%) had excellent, 7 patients (23%) had good, and 2 patients had fair (7%) results.

<b>SUBJECTIVE EVALUATION</b>	<b>NUMBER OF PATIENTS</b>
Excellent	21
Good	7
Fair	2
Poor	0
Total	30





OBJECTIVE EVALUATION

Loss Of Dorsiflexion (<45 degrees)	0
Loss Of Palmar Flexion (<30 degrees)	3
Loss Of Ulnar Deviation (< 15 degrees)	1
Loss Of Radial Deviation (< 15 degrees)	2
Loss Of Supination (< 50 degrees)	1
Loss Of Pronation (< 50 degrees)	1
Loss Of Circumduction	1
Pain at DRUJ	0
Grip Strength $\leq$ 60% of opp. side	1

COMPLICATIONS

Reflex Sympathetic Dystrophy	nil
Joint stiffness	3
Paraesthesia in the distribution of radial nerve	1
Impingement of tendons	nil
Median Nerve Complications	nil

## **RESULTS**

### **ANATOMICAL SCORE OF HEALED FRACTURE**

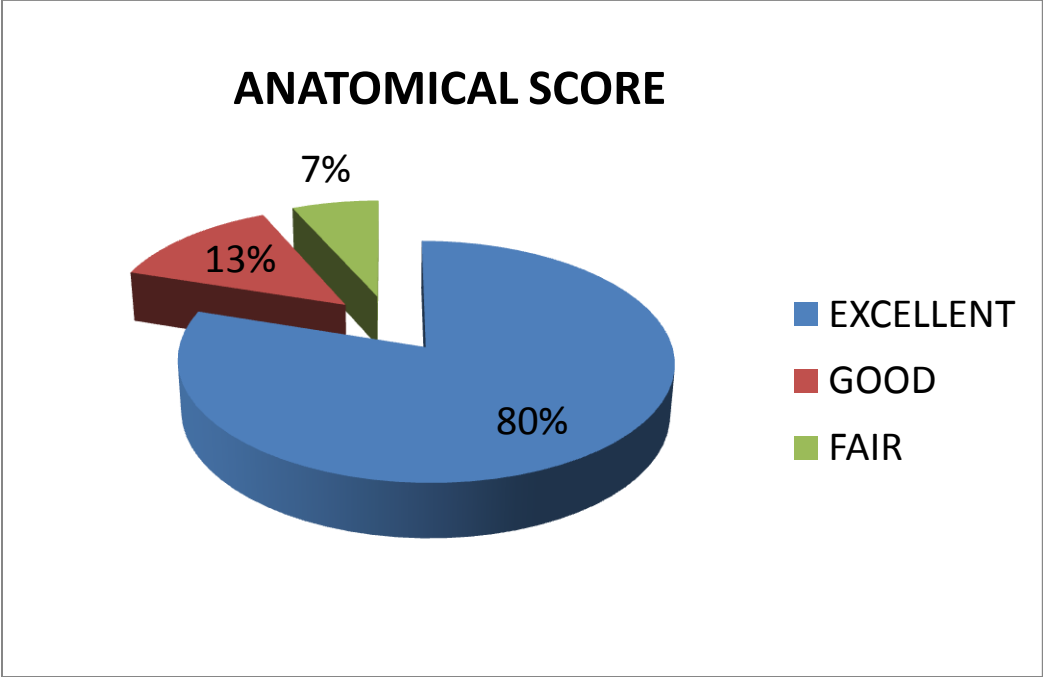
The scoring was done according to the Sarmiento's modification of Lind Strom Criteria.

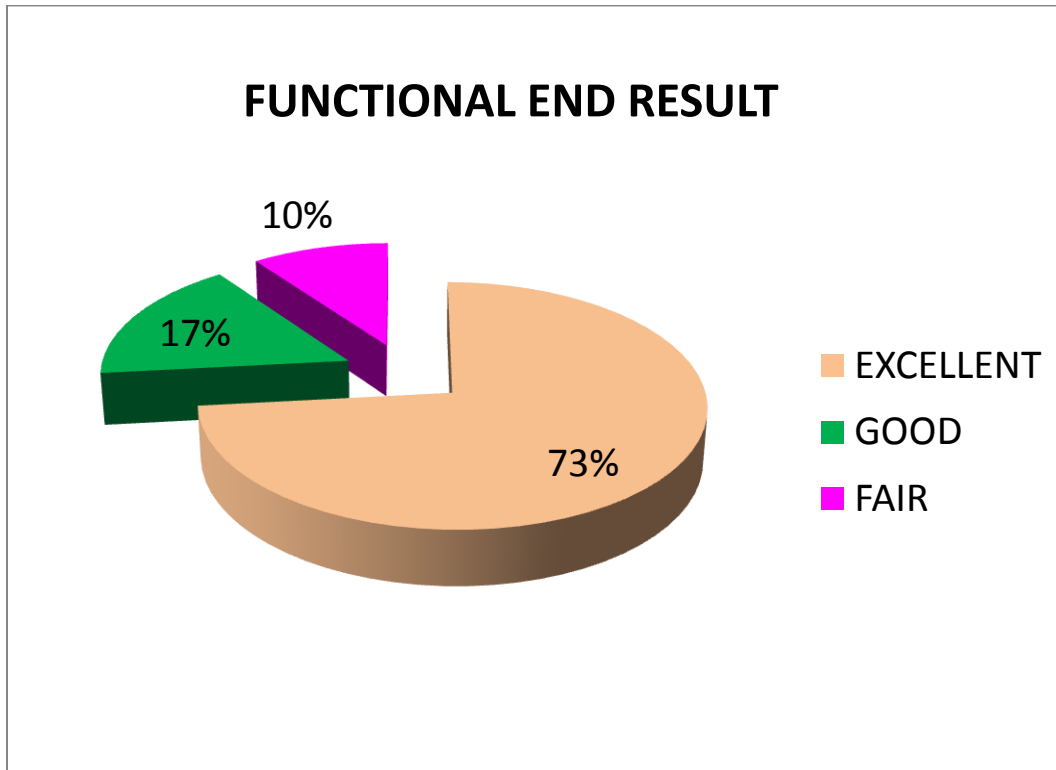
Anatomically 24 patients (80%) had excellent restoration of anatomy, 4 patients (13%) had good restoration and 2 had fair (7%) restoration of anatomy. Thus 93% patients had excellent to good alignment of fragments and good reduction could not be achieved in 7% patients resulting in fair or poor results.

### **FUNCTIONAL END RESULT OF HEALED FRACTURE**

The scoring of healed fracture was done as according to the demerit point system of Gartland and Werley with Sarmiento et al's modification.

Functionally 22 patients (73%) had excellent, 5 good (17%) and 3 patients had fair (10%) restoration of functions. Poor function correlated with residual displacement and poor patient compliance.





## **CONCLUSION**

93% anatomical and 90% functional, excellent to good results, suggests that stabilizing the fracture fragments with volar plate and screws in the management of the fractures of distal radius, is an effective method to maintain the reduction till union and prevent collapse of the fracture fragments, even when the fracture is grossly comminuted/intra-articular/unstable and/or the bone is osteoporosed.

The technique emphasises that open reduction and internal fixation with volar plating has excellent functional outcome with minimal complications thus proving that it is the prime modality of treatment for distal radius fractures. The

procedure is applicable for AO types A, B and C fractures of the distal radius, in young patients with a good bone stock as well as in elderly osteoporotic patients.

## **BIBLIOGRAPHY**

1. Colles A. On the fracture of the carpal extremity of the radius. Edinburgh Med Surg 1814;10:182–6.
2. Bacorn RW, Kurtzke JF: Colles' Fracture: A study of two thousand cases from the New York states Compensation Board. J Bone Joint Surg 1953; 35A: 643-658.
3. Fernandez DL: Correction of posttraumatic wrist deformity in adults by osteotomy, bone grafting and internal fixation. J Bone Joint Surg 1982;64A:1164 – 1178
4. Zemel NP: The prevention and treatment of complications from fractures of the distal radius and ulna. Hand Clin. 1987;3:1 – 11
5. Robert W. Bucholz, MD, James D Heckman, MD: Rockwood Greens Fractures in Adults. 5<sup>th</sup> edition, Lippincott Williams & Wilkins 2001 Volume I: 815 – 867
6. Neal C. Chen, MD; Jupiter JB, MD : Current Concepts Review, Management Of Distal radial fractures. J Bone Joint Surg Am. 2007;89:2051-62
7. Bartosh RA, Saldana MJ. Intra-articular fractures of the distal radius: a cadaveric study to determine if ligamentotaxis restores radiopalmar tilt. J Hand Surg [Am] 1990;15(1):18-21

8. Rikli DA, Regazzoni P. Fractures of the distal end of the radius treated by internal fixation and early function. A preliminary report of 20 cases. *J Bone Joint Surg Br* 1996;78(4):588–92.
9. Szabo RM. Distal radioulnar joint instability. *J Bone Joint Surg [Am]* 2006;88(4):884–94.
10. Smith R. *A Treatise on Fractures in the Vicinity of Joints and on Certain Forms of Accidental and Congenital Dislocations*. Dublin: Hodges and Smith, 1854.
11. Frykman GK. Fracture of the distal radius including sequelae shoulder hand finger syndrome. Disturbance in the distal radioulnar joint and impairment of nerve function. A clinical and experimental study. *Acta Orthop Scand Suppl* 1967;108:1–155.
12. Weber ER: A rationale approach for the recognition and the treatment of Colles' fracture. *Hand Clin* 1987;3:3 – 21
13. Thomas F. Reduction of Smith's fracture. *J Bone Joint Surg* 1957; 39B:463.
14. CP. Articular fractures of the distal radius. *Orthop Clin North Am* 1984;15:217–36.
15. Metz VM, Gilula IA: Imaging techniques for distal radius fractures and related injuries. *Orthop. Clin. North Am.* 24:217-228,1993
16. Nana AD, Joshi A, Lichtman DM. Plating of the distal radius. *J Am Acad Orthop Surg* 2005;13:159–71.
17. Hardy DH, Totty G, Renuis WR et al: Posteroanterior wrist radiography: Importance of arm positioning. *J. Hand Surg* 12A;504,1987

18. Jones R (ed): Injuries of joints. London, England, Henry Frowde & Hodder & Stoughton, 1915, p 110
19. Bohler L (ed): The Treatment of Fractures. Vienna, Austria, W Maudrich,1929.
20. Connolly J. Fractures and Dislocations. Closed Management. Philadelphia: WB Saunders, 1995
21. Charnley J. The mechanics of conservative treatment. In: The closed treatment of common fractures. London: Greenwich Medical Media; 2003. p. 43–59.
22. Sarmiento A, Pratt GAW, Berry NC, Sinclair WF: Colles' fractures: Functional Bracing in supination. *J Bone Joint Surg* 1975;57A:311-317.
23. Weber ER: A rationale approach for the recognition and the treatment of Colles' fracture. *Hand Clin* 1987;3:3 – 21
24. Castaing J: Recent fractures of the inferior extremity of the radius in the adult (French). *Rev Chir Orthop* 50:582-696, 1964
25. Kapandji A: Bone fixation by double percutaneous pinning. Functional treatment of non-articular fractures of the distal radius [French]. *Ann Chir Main* 30:903-908,1976
26. Rayhack J, Langworthy J, Belsole R: Transulnar percutaneous pinning of displaced distal radial articular fractures. Presented at the American Society for surgery of the Hand Annual meeting. Orlando, FL, October 3,1991
27. Anderson R, O'Neil G: Comminuted fractures of the distal end radius. *Surg Gynecol Obstet* 1944; 78: 434-440.
28. Agee JM: External Fixation: Technical advances based upon multiplanar ligamentotaxis. *Orthop Clin North Am* 1993;24:265-274

29. Kamano M, Honda Y, Kazuki K, et al. Palmar plating for dorsally displaced fractures of the distal radius. *Clin Orthop Relat Res* 2002;397:403–8.
30. Rozental T, Blazar P. Functional outcome and complications after volar plating for dorsally displaced, unstable fractures of the distal radius. *J Hand Surg [Am]* 2006;31(3):359–65
31. Burke EF, Singer RM. Treatment of comminuted distal radius with the use of an internal distraction plate. *Tech Hand Up Extrem Surg* 1998;2(4):248–52.
32. Chung KC, Watt AJ, Kotsis SV et al. Treatment of unstable distal radial fractures with the volar locking plating system. *J Bone Joint Surg Am* 2006; 88 2687-2694.
33. Rozental TD, Beredjiklian PK, Steinberg DR, et al. Open fractures of the distal radius. *J Hand Surg [Am]* 2002;27(1):77–85.
34. Bonatz E, Kramer TD, Masear VR. Rupture of the extensor pollicis longus tendon. *Am J Orthop* 1996;25(2):118–22.
35. Gelb RI. Tendon transfer for rupture of the extensor pollicis longus. *Hand Clin* 1995;11(3):411–22.
36. Rozental TD, Blazar PE. Functional outcome and complications after volar plating for dorsally displaced, unstable fractures of the distal radius. *J Hand Surg [Am]*.2006; 31:359 -65
37. Arora R, Lutz M, Hennerbichler A, Krappinger D. Complications following internal fixation of unstable distal radius fracture with a palmar locking-plate. *J Orthop Trauma* May 2007; 21 (5) 316-22.
38. McQueen M, Caspers J. Colles fracture: does the anatomical result affect the final function? *J Bone Joint Surg [Br]* 1988;70(4):649–51.



39. Hertel R, Pisan M, Lambert S, Ballmer FT (1996) Plate osteosynthesis of diaphyseal fractures of the radius and ulna. *Injury*27:545–548.
40. Prommersberger KJ, Fernandez DL. Non union of distal radius fractures. *Clin Orthop Relat Res* 2004;419:51–6.
41. Park MJ, Cooney WP, Hahn ME, et al. The effects of dorsally angulated distal radius fractures on carpal kinematics. *J Hand Surg [Am]* 2002;12(2):223–32.
42. Sarmiento A, Pratt GAW, Berry NC, Sinclair WF: Colles’ fractures: Functional Bracing in supination. *J Bone Joint Surg* 1975;57A:311-317.
43. Amit Kumar Srivastava : Fracture Distal End Radius, Evaluation Of Cosmetic And Functional Outcome Following Various Methods Of Treatment *J.Orthopaedics* 2008;5(3)e5
44. Distal Radius Fractures Frank A. Liporace, MD, Mark R. Adams, MD, John T. Capo, MD, and Kenneth J. Koval, MD (*J Orthop Trauma* 2009;23:739–748)
45. Villar RN, Marsh D, Rushton N, Greatorex RA: Three years after Colles’ Fracture. A prospective review. *J Bone Joint Surg* 69B: 635-638
46. Tsukazaki T, Takagi, Iwasaki K: Poor correlation between functional results and radiographic findings in Colles’ fracture. *J Hand Surg* 1993;18B:588-591.